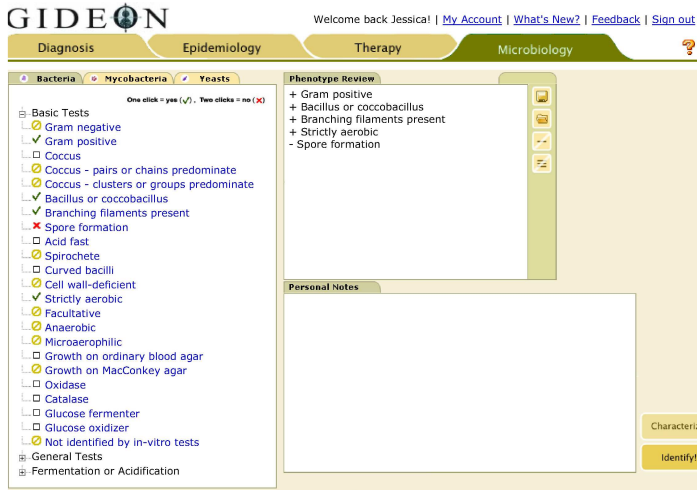


“Creative De-Bugging” Exploration of GIDEON’s Microbiology Module

A 47 year old man is found to have a large abscess in his left leg. Routine cultures reveal a branched, aerobic, non-sporulating, Gram-positive bacillus. What micro-organisms should be considered ? What procedure should the laboratory perform at this point ?

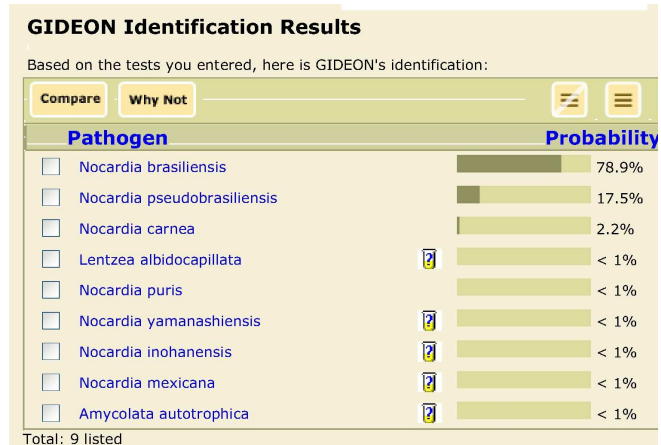
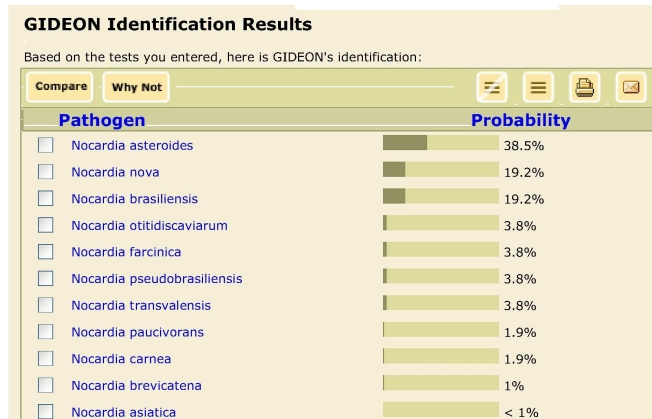
Phenotypic tests were entered into the Microbiology module of GIDEON:



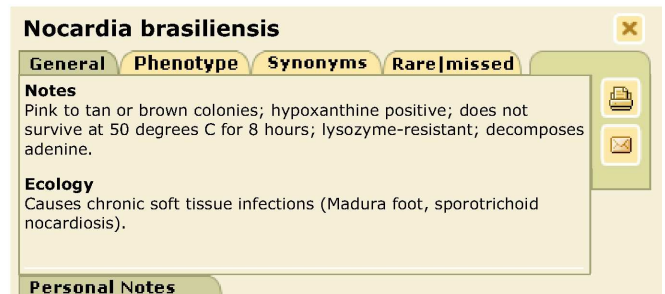
Tests	Nocardia asteroides	Nocardia nova	Nocardia brasiliensis	Nocardia otitidiscaviarum	Nocardia farcinica	Nocardia pseudobrasiliensis
Citrate	-	-	-	-	-	-
myo-Inositol	-	-	-	-	-	-
D-Mannitol	-	-	-	-	-	-
L-Rhamnose	-	-	-	-	-	-
Esculin hydrolysis	-	-	-	-	-	-
Sucrose	-	-	-	-	-	-
Trehalose	-	-	-	-	-	-
Maltose	-	-	-	-	-	-
Nitrate to nitrite	-	-	-	-	-	-
Casein hydrolysis	-	-	-	-	-	-
Glucose fermenter	-	-	-	-	-	-
Tyrosine hydrolysis	-	-	-	-	-	-
Urea hydrolysis	-	-	-	-	-	-
D-Mannose	-	-	-	-	-	-
D-Sorbitol	-	-	-	-	-	-
Glucose oxidizer	-	-	-	-	-	-
Xanthine hydrolysis	-	-	-	-	-	-
L-Arabinose	-	-	-	-	-	-

Our organism was 'positive' for all three additional tests. After re-identifying the organism we can see in the following screen that the most likely identification in this case is *Nocardia brasiliensis*.

Pressing the 'Identify' button results in the following screen:



Additional clinical and bacteriological hints are displayed when we click on the organism name:



The organism in question appears to be one of several species of *Nocardia*. In order to determine the most discriminative laboratory test to perform at this point, we will check all of the organisms, and press 'Compare'. As we see in the next screen, GIDEON recommends that we examine Citrate, myo-Inositol and Mannitol [top three tests].

To try GIDEON sign up for a **FREE** trial at www.GIDEONonline.com